

Equine Thermography Case Study

Intermittent Lameness

16 hh ten-year-old TB Gelding, ex racehorse

This horse was retired from racing due to left front leg injury (the present owner had no knowledge of the exact nature of the injury), had time off to recover and was recently brought back into work. The horse's mobility was initially sound but the animal began to show lameness. A vet was not yet called as the lameness was intermittent.

Pre- and post-exercise scans were taken (about 120 images) at an ambient temperature of 20°C.

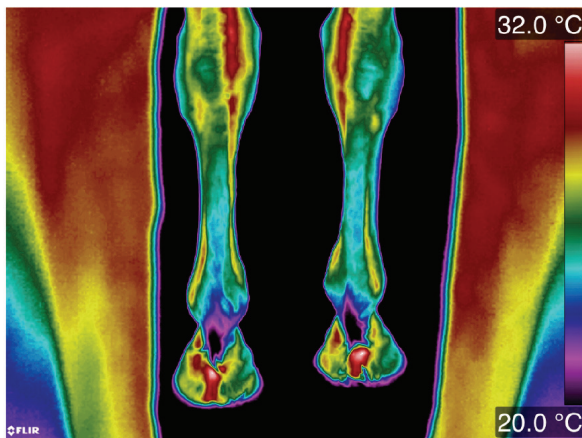


Figure 1. Distal front limbs palmar view – Pre-exercise

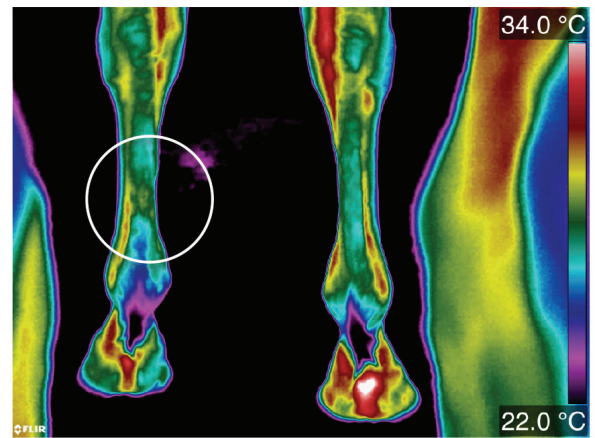


Figure 2. Distal front limbs palmar view – Post-exercise

Taking all of the images into consideration, looking at symmetry and analysing pre- and post-exercise images, it was possible to see that this horse had an asymmetric abnormal thermal pattern in the left front distal palmar view post exercise (circled white) and by analysing the solar views it could be seen that the horse was not placing so much weight on the left front limb as he was on the right front limb, adding to the evidence that it was this region that required further investigation by a vet.

